

## Can we Measure a Woman's Cancer Risk When Breast Implants are Present? – YES!!!

Richard M Fleming<sup>1\*</sup>, Matthew R Fleming<sup>1</sup>, Tapan K Chaudhuri<sup>2</sup> and William C Dooley<sup>3</sup>

<sup>1</sup>FHHI-OmnificImaging-Camelot Los Angeles, CA, USA

<sup>2</sup>Eastern Virginia Medical School Norfolk, VA, USA

<sup>3</sup>Oklahoma University Health Science Center Oklahoma City, Oklahoma

### \*Corresponding author

Richard M Fleming, FHHI-OmnificImaging-Camelot Los Angeles, CA, USA

Submitted: 25 Feb 2020; Accepted: 05 Mar 2020; Published: 04 Apr 2020

### Abstract

**Background:** Breast implants are now recognized to be associated with a variety of potential problems, including inflammatory changes – both locally and systemically – precancerous and cancerous changes. Monitoring these changes are particularly problematic in the face of breast implants. Molecular breast imaging (MBI) using FMTVDM\* provides a unique method for measuring changes in breast tissue in these individuals. This study examines that potential.

**Methods:** Eighteen breast implants were evaluated in women who had undergone implantation for a variety of reasons. These women underwent measurement of regional blood flow (RBF) and metabolism differences to determine the extent of inflammation, precancerous and cancerous changes.

**Results:** Measured changes in RBF and metabolism were not influenced by breast implants. Among the 18 breast implant studies; there were 4 instances of inflammation (22%), 5 (28%) instances of precancerous changes and 1 (5%) instance of breast cancer.

**Conclusions:** MBI using FMTVDM provides a non-invasive ability to measure changes in breast tissue in women who have undergone breast implantation. The measured monitoring of these changes allows clinicians a tool to make clinical decisions regarding either the need to remove the breast implant or provide alternative treatment options.

**Keywords:** FMTVDM, Breast Cancer, Inflammation, Breast Implants

### Introduction

The risk of inflammatory changes, potential autoimmune diseases and breast cancer in women with breast implants are now well recognized [1-6]. Given the prevalence of breast implants and the likelihood that they will not become a thing of the past, it is important that clinicians be able to monitor the overall health of the women and men with breast implants by measuring changes in breast health [7-9]. This study investigated the prevalence of inflammatory changes in women with breast implants and monitored those changes by measuring metabolic and regional blood flow (RBF) differences associated with inflammatory and cancerous breast changes using FMTVDM\* molecular breast imaging.

### Methods

**Patient enrollment:** Eighteen breast implants were interrogated in women with breast irregularities. The women volunteered to undergo FMTVDM molecular breast imaging (MBI), to measure changes in breast tissue RBF and metabolism, to determine if there was evidence of inflammation, precancerous changes or cancer. Their mammography findings were compared along with the information already known about the extent of their breast health. All components of FMTVDM are already FDA approved - including the enhancement

of regional blood flow (RBF) and metabolic differences, isotopes and camera. Each woman signed an informed consent agreeing to participate in the nuclear imaging protocol. All personal identifying information was redacted to protect patient identification.

**Breast Imaging:** Prior to imaging, the nuclear technologist calibrated the Siemens' Orbiter camera according to patent instructions to guarantee quantitative calibration of the camera in addition to customary qualitative controls.

Patients arrived in the overnight fasting state and were prepared for imaging with placement of an intravenous catheter through which a vasodilator (enhancement) was given, followed by the imaging isotope and flush as previously described [7-9].

**Patient records:** Patients provided *inter alia* detailed medical records, including prior biopsy results, mammography results, family history of cancer, any prior false positive or false negative (FPFN) results from prior testing including but not limited to mammography, smoking history, current medications, any diagnosis of dense breasts and breast implants.

**Measurement of RBF and metabolic differences - Maximal Count Activity (MCA):** Following image acquisition, regions of interest (ROI) were drawn around the acquired breast images and

the measured scintillation activity of RBF and metabolic differences was obtained (MCA).

## Results

The diagnostic information obtained from these 18 breast implants and patient medical records/information are shown in Table 1, including specific details for each region of interest (ROI) measured, along with the patient number and breast involved. The measured MCA for each ROI is shown, along with tissue information, the presence or absence of breast implants, dense breasts and FP mammography results.

**Table 1: Patient data and diagnostic information for 18-breast implants**

Initial-Breast	MCA	Tissue Data	Other
1-R	54	Lumps	Implants, Not Dense
2-L	74	Lumps	Implants, Not Dense
3-L	92	No CA	Breast Implant
4-R	103	None CA Lumps	Breast Implant
5-L	144	No CA	Breast Implant
6-L	146	Irregularities	Dense Breasts, Implants
7-R	158	No CA	Breast Implant
8-R	169	Lumps	Implants, Not Dense
9-L	173	Non-CA Lumps	Breast Implant, Taking HT
10-L	180	Lumps	Implants, Not Dense
11-L	232	No CA	Breast Implant
12-R	238	No CA	Breast Implant
13-R	245	Lumps	Implants, Not Dense
14-L	259	Irregularities	Dense Breasts, Implants
15-R	270	Not tested yet	?
16-R	290	CA with marker left	Dense Breasts, Implants
17-L	297	Lumps	?
18-R	417	CA with marker left	Dense Breasts, Implants

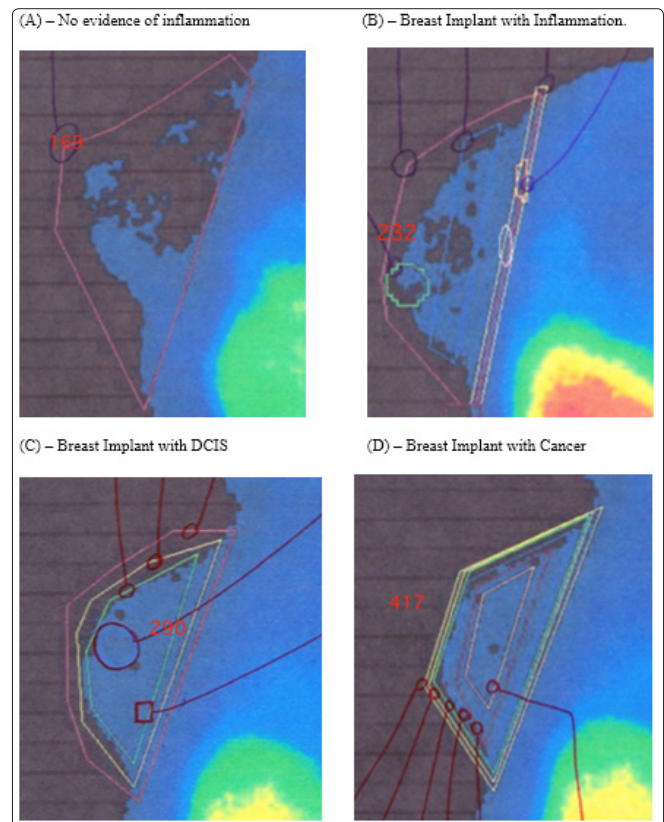
DB = Dense Breasts (Yes, No, ?=Uncertain), FP=incorrect mammogram, HT=Hormone Therapy

The MCAs were compared with the previously published [7,8] values for breast tissue including women without inflammation or cancer (MCA  $144 \pm 30$ ; 95% CI 138-150), women with inflammation (MCA  $229 \pm 50$ ; 95% CI 219-240) and women with breast cancer (MCA  $446 \pm 80$ ; 95% CI 404-489). Later research [7,9] showed pre-cancerous and DCIS tissue to have MCA values of  $307 \pm 29$ ; 95% CI 270-340.

Of the 18-implants, there was evidence of inflammation in 4 (22%), five had evidence of precancerous changes (28%) and 1 (5%) had evidence of breast cancer.

Examples of FMTVDM breast implant imaging results are shown in Figure 1, including (A) no evidence of inflammation or cancer

(normal), (B) inflammatory changes, (C) ductal carcinoma in-situ and (D) breast cancer.



**Figure 1: Results of FMTVDM measurements in women with breast implants**

## Discussion

While the sample size was relatively small, it provided adequate information to demonstrate that changes in breast tissue inflammation, precancerous and cancerous changes are measurable in women with breast implants. In this study, one-third of the implants were associated with precancerous or cancerous changes in the breast and twenty two (22%) percent were associated with inflammation. There was one instance of breast cancer.

While the purpose of this study was not to conclude that the breast implants were the cause of the changes in breast tissue, it demonstrated the ability to measure the tissue changes occurring behind the breast implants.

Women will undoubtedly continue to have breast implants for a variety of reasons. Perhaps the most clinically important are women who have undergone reconstructive surgery post mastectomy for the treatment of breast cancer. In these women there is a particular risk for recurrence of cancer, which becomes more difficult to evaluate in the presence of breast implants presenting a special challenge for clinicians [10,11]. Breast implants do not affect MCA measurement as the isotope is not taken up into the implants, allowing clear measurements to be obtained in the presence of breast implants [7]. Thus, allowing these women, and men, to be safely monitored for evidence of tissue change in the face of breast implants.

## Conclusions

Using FMTVDM, women and men with breast implants can be monitored for changes in breast tissue including inflammation, precancerous and cancer change – alerting clinicians to possible concerns and the need for implant extraction or other treatment [2].

\*FMTVDM = The Fleming Method for Tissue and Vascular Differentiation and Metabolism

**Acknowledgments:** FMTVDM is a utility patent issued to first author. All figures and material reproduced with the expressed consent of first author.

All procedures performed in studies involving human participants were in accordance with the ethical standards of the institutional and/or national research committee and with the 1964 Helsinki declaration and its later amendments or comparable ethical standards.

## References

1. Bizjak M, Selmi C, Praprotnik S, Or Bruck, Carlo Perricone, et al. (2015) Silicone implants and lymphoma: The role of inflammation. *J Autoimmun* 65: 64-73.
2. De Boer M, Colaris M, van der Hulst RRWJ, Cohen Tervaert JW (2017) Is explantation of silicone breast implants useful in patients with complaints? *Immunol Res* 65: 25-36.
3. Orciani M, Sorgentoni G, Olivieri F, Mattioli-Belmonte M, Di Benedetto G, et al. (2017) Inflammation by Breast Implants and Adenocarcinoma: Not Always a Bad Company. *Clin Breast Cancer* 17: 286-292. Corrigendum *Clin Breast Cancer* 2018.
4. Cohen Tervaert JW, Colaris MJ, van der Hulst RR (2017) Silicone breast implants and autoimmune rheumatic diseases: myth or reality. *Curr Opin Rheumatol* 29: 348-354.
5. Leberfinger AN, Behar BJ, Williams NC, Kevin L Rakszawski, John D Potochny, et al. (2017) Breast Implant-Associated Anaplastic Large Cell Lymphoma: A Systematic Review. *JAMA Surg* 152: 1161-1168.
6. Collett DJ, Rakhorst H, Lennox P, Magnusson M, Cooter R, et al. (2019) Current Risk Estimate of Breast Implant-Associated Anaplastic Large Cell Lymphoma in Textured Breast Implants. *Plast Reconstr Surg* 143: 30S-40S.
7. The Fleming Method for Tissue and Vascular Differentiation and Metabolism (FMTVDM) using same state single or sequential quantification comparisons. Patent Number 9566037. Issued 02/14/2017.
8. Fleming RM, Dooley WC (2002) Breast enhanced scintigraphy testing distinguishes between normal, inflammatory breast changes, and breast cancer: a prospective analysis and comparison with mammography. *Integ Ca Ther* 1: 238-245.
9. Fleming RM, Fleming MR (2019) The Importance of Thinking about and Quantifying Disease like Cancer and Heart Disease on a “Health-Spectrum” Continuum. *J Compr Cancer Res* 3: 1-3.
10. Remacle S, Lifrange E, Nizet JL (2015) Management of breast cancer in a woman with breast implants. *Rev Med Liege* 70: 32-36.
11. Cho EH, Shamma RL, Phillips BT, Greenup RA, Hwang ES, et al. (2017) Breast Cancer after Augmentation: Oncologic and Reconstructive Considerations among Women Undergoing Mastectomy. *Plast Reconstr Surg* 139: 1240e-1249e.

**Copyright:** ©2020 Richard M Fleming. This is an open-access article distributed under the terms of the Creative Commons Attribution License, which permits unrestricted use, distribution, and reproduction in any medium, provided the original author and source are credited.